



**PATIENT:** Jane Doe      **ACCESSION NUMBER:** S13-07039  
*REQUISITION#:* 1111111    *SSN:* 123456789  
*D.O.B:* 01/01/1885      *AGE/SEX:*                      *CLIA#:* 17D1027743  
*PHYSICIAN:* Dr. Doe    *DATE COLLECTED:* 7/22/2013  
*PRACTICE NAME:* Cypress    *DATE RECEIVED:* 7/22/2013  
*SUBMITTING FACILITY:* Cypress    *DATE REPORTED:* 7/23/2013 12:12 PM  
*COPY TO:* MD

## HEARTLAND PATHOLOGY

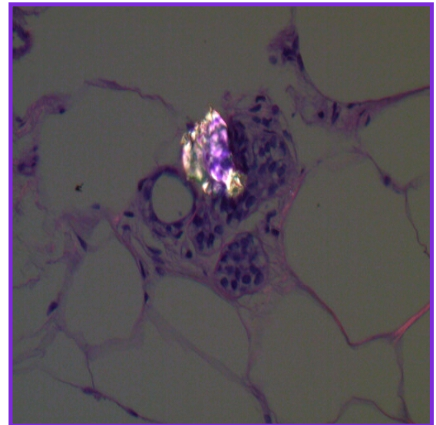
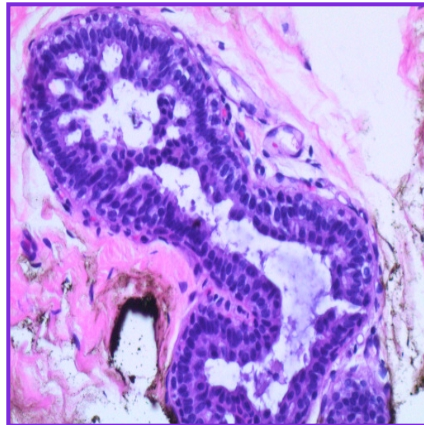
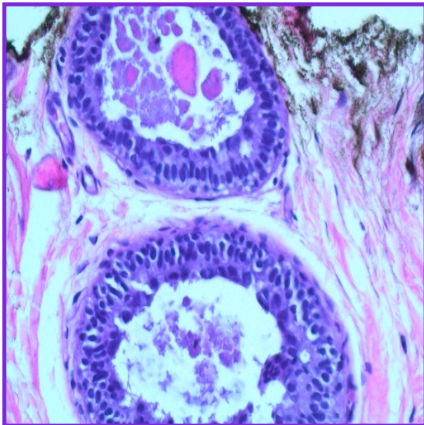
### SURGICAL PATHOLOGY REPORT

#### **DIAGNOSIS:**

**LEFT BREAST, 6:00, ULTRASOUND-GUIDED BIOPSY:**

**-MAMMARY TISSUE WITH MILD FIBROCYSTIC CHANGES: STROMAL FIBROSIS AND FOCAL USUAL DUCTAL HYPERPLASIA. MICROCALCIFICATION IN BENIGN BREAST PROFILE.**

**-NEGATIVE FOR ATYPIA AND MALIGNANCY.**



The digital images depicted above are representative images only, and should not be used as a diagnostic tool.

#### **COMMENT:**

#### **CLINICAL INFORMATION:**

6mm irregular mass with calcifications. ?DCIS vs IDC vs fibrosis. History of DCIS is 2007.

#### **SOURCE OF SPECIMEN:**

LEFT BREAST, 6:00, ULTRASOUND-GUIDED BIOPSY

#### **GROSS DESCRIPTION:**

The specimen is received in formalin fixative in a specimen container labeled with patient name "Jane Doe, left breast, 6:00, ultrasound-guided biopsy" and a requisition number which matches that on the form. The specimen consists of multiple tan yellow colored elongated breast tissue cores ranging in size from 3 x 0.2 x 0.2 cm to 0.2 x 0.2 x 0.1 cm. The specimen is inked black. The specimen is submitted entirely into one cassette, A1. KR/wt 07/22/13



**HEARTLAND**  
**PATHOLOGY**

**PATIENT: Jane Doe**      **ACCESSION NUMBER: S13-07039**  
*REQUISITION#:* 1111111    *SSN:* 123456789  
*D.O.B:* 01/01/1885      *AGE/SEX:*                      *CLIA#:* 17D1027743  
*PHYSICIAN:* Dr. Doe    *DATE COLLECTED:* 7/22/2013  
*PRACTICE NAME:* Cypress    *DATE RECEIVED:* 7/22/2013  
*SUBMITTING FACILITY:* Cypress    *DATE REPORTED:* 7/23/2013 12:12 PM  
*COPY TO:* MD

---

**MICROSCOPIC DESCRIPTION:**

Microscopic evaluation is performed. JD/jd 07/23/13